Retinal PHYSICIAN®
November/December 2011

Surgical Management of Difficult Cases

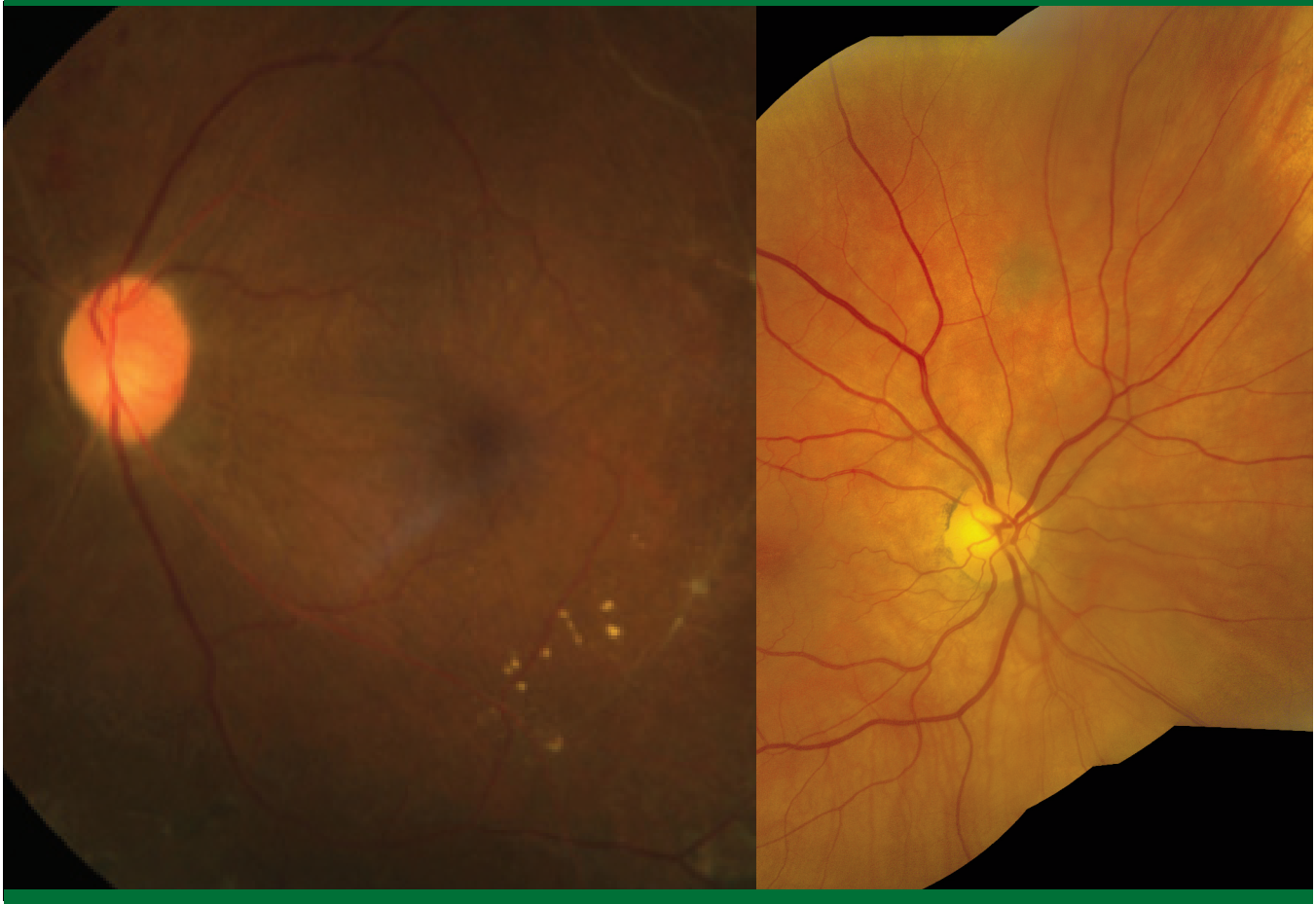

Contributing Faculty:
Maria H. Berrocal, MD
Timothy G. Murray, MD, MBA, FACS
Carl D. Regillo, MD, FACS
Wayne Solley, MD

Today in vitreoretinal surgery, things are coming together — literally. We have seen some very significant advances make their way into our ORs in a relatively short period of time. After a somewhat slow start, microincisional vitrectomy surgery (MIVS) is becoming the preferred approach for a growing number of surgeons. MIVS, with its newly designed cannulated trocars and small-gauge instruments, now allows truly robust removal of core vitreous and outstanding control of the surgical field on par with its 20-gauge predecessor.

The performance of small-gauge instrumentation has been driven forward further by its marriage with the latest surgical platforms, which integrate multiple devices into single systems and feature advanced fluidics, vitreous cutting technology and IOP control. Notably, our newest posterior segment platforms incorporate state-of-the-art anterior segment capabilities. In the case of the CONSTELLATION® Vision System (Alcon), a 532-nm laser is integrated as well.

Together, these types of advances enable more efficient surgery, and more efficiency means enhanced safety. Today's technologies benefit surgeons and their practices and, most importantly, patients. In this supplement to *Retinal Physician*, surgeons describe what they consider to be the benefits of the CONSTELLATION® Vision System, in particular when performing challenging complex procedures.

Dr. Maria Berrocal explains how small-gauge instruments improve her ability to approach complex retinal detachments. The retina is stabilized by advanced fluidics, and aggressive membrane dissection can be accomplished with the small-gauge cutters, greatly reducing the need for forceps and scissors. Enhanced intraoperative IOP control reduces bleeding during treatment of diabetic traction and rhegmatogenous retinal detachments. The integration of laser technology, wide-field viewing and small-gauge illumination probes allows extensive anterior laser therapies that were difficult to perform in the past.

Dr. Carl Regillo outlines the steps surgeons are taking in order to improve outcomes in surgery for retained lens material. He points out how current fluidics and high-speed vitrectomy probes sometimes allow management of these cases without the need for primary pars plana lensectomy.

Dr. Wayne Solley reports on his new technique for removing an IOL that has dislocated into the vitreous. Taking advantage of the efficient core vitrectomy, well-controlled surgical field and bright chandelier lighting provided by the CONSTELLATION® System, he cuts the IOL into several pieces and removes them through the pars plana, eliminating the need for an additional anterior segment incision.

Finally, I describe how current thinking about the approach to management of co-existing retinal pathology and cataract has been evolving. The CONSTELLATION® System, now equipped with OZil® torsional phaco technology, is a major factor in making one trip to the OR for these patients instead of two a viable option. We are finding that combined surgery results in less related morbidity for patients as well as faster healing and recovery of visual acuity.

— Timothy G. Murray, MD, MBA, FACS

BY MARIA H. BERROCAL, MD

Reducing Complications in Diabetic Retinal Detachments

A state-of-the-art surgical platform helps this surgeon stay a step ahead of bleeding and iatrogenic breaks.

Since I first began using microincision vitrectomy surgery (MIVS), my thinking about its usefulness has evolved. Today, I use MIVS not only for routine but complex cases, as well (Figure 1). From the start, MIVS was a promising opportunity to use small, self-sealing incisions to reduce surgical trauma, induced astigmatism, inflammation and patient discomfort and foster more rapid visual recovery. Among the most complex cases I see in my practice setting, which has a large diabetic patient population, are traction retinal detachments and combination traction/rhegmatogenous retinal detachments. An impressively long list of factors has increased my use of MIVS in these cases over time.

Compared with earlier years, we now have more rigid 23- and 25-gauge instruments, a wider variety of compatible instruments, brighter light sources, more efficient vitreous removal thanks to specially designed higher-speed cutting probes and fluidics, insertion systems that ease entry into the eye and create more securely sealing incisions, and surgical platform features that enhance surgeon control of several surgical parameters. My surgical platform of choice, the CONSTELLATION® Vision System (Alcon), incorporates all of the latest advancements in these areas. However, in this article, I highlight how I use it in the high-risk eyes of diabetic patients with traction and combination traction/rhegmatogenous retinal detachments.

INDICATIONS, GOALS FOR SURGERY

Surgical intervention becomes necessary when a traction detachment involves, or is threatening to involve, the fovea. In order to reattach the retina, we must remove the fibrovascular tissue that is causing the detachment. Surgery is needed for a combination traction/rhegmatogenous detachment because we have not only the traction component but also the entire retina may be detached and mobile. In order to reattach in these cases, we must remove all of the tractional fibrovascular tissue from all areas of the retina and treat the retinal tears with laser.

REDUCING SCLEROTOMY-RELATED ISSUES

We see the benefits of MIVS from the outset of each case because the smaller sclerotomies and trocars have addressed most of the complications experienced with this aspect of vitrectomy in the past. For example, we no longer have to worry that when we raise IOP to control bleeding, the detached retina might come out of the wound, causing a retinal break. Also, the smaller trocars and cannulas may be less traumatic to the vitreous base. Therefore, postoperative neovascularization of the vitreous base, growing in through the sclerotomies, is maybe less of an issue.

New valved cannulas are now available for the CONSTELLATION® System. The valves prevent fluid from leaving the eye as instruments are being inserted and removed, which contributes to a more stable operative environment.

PREVENTING IATROGENIC BREAKS

As we are all well aware, iatrogenic breaks in the retina are one of the most unfortunate potential complications we face while working in diabetic eyes with retinal detachments. 25-gauge surgery with the CONSTELLATION® System contributes to a reduction in vitreous traction as vitreous is removed. I describe the system's performance as essentially erasing vitreous without significant movement of the underlying retina. The

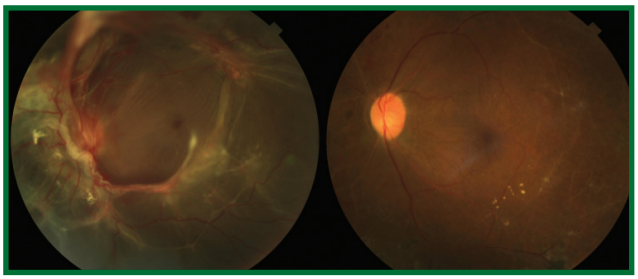

Figure 1. Traction and rhegmatogenous retinal detachment before and after 23-gauge surgery.

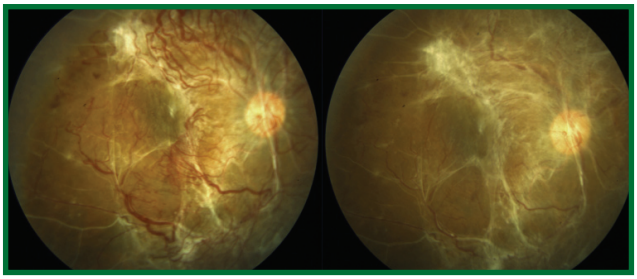

Figure 4. Reduced vascularity of abnormal tissue in an eye treated with an intravitreal injection of bevacizumab prior to vitrectomy for retinal detachment repair.

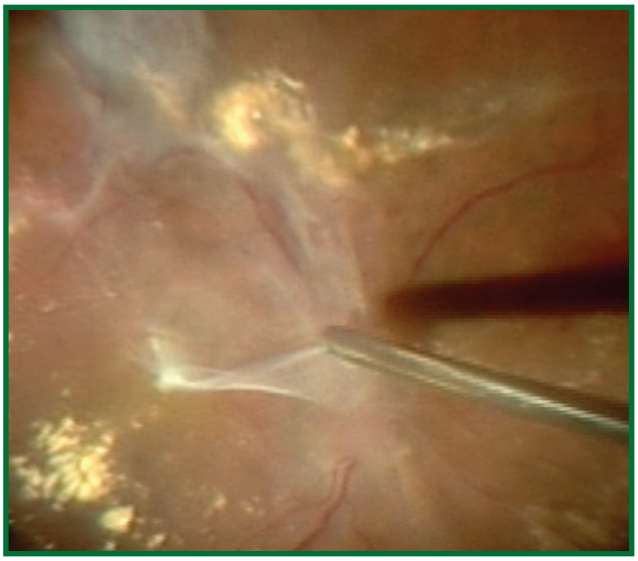

Figure 2. The 25-gauge ULTRAVIT® High Speed Vitrectomy Probe utilized as a forceps with suction only during surgery performed with the CONSTELLATION® Vision System.

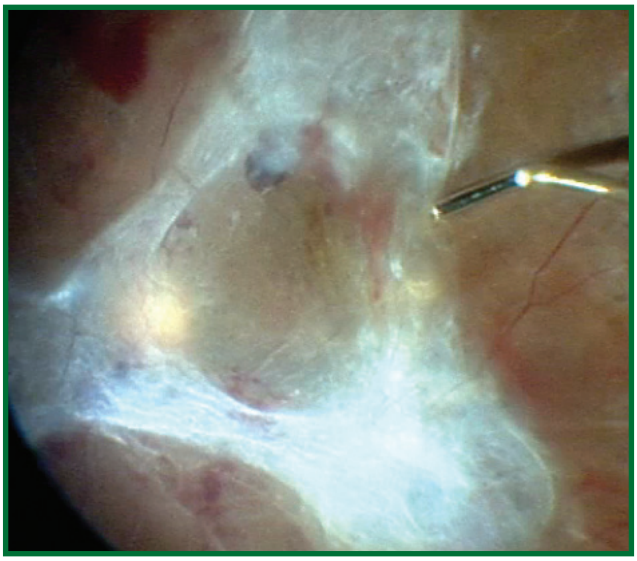

Figure 5. Viscodissection helps to lift fibrovascular tissue so it can be removed more easily with the vitrectomy probe.

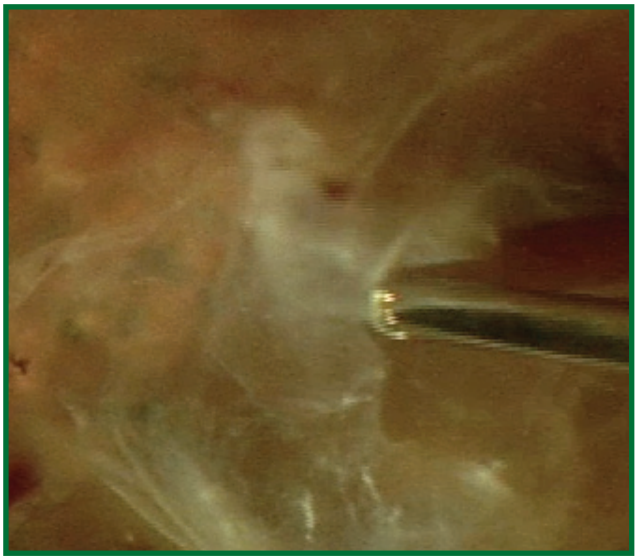

Figure 3. The 25-gauge ULTRAVIT® High Speed Vitrectomy Probe utilized as scissors to segment membranes during surgery with the CONSTELLATION® Vision System.

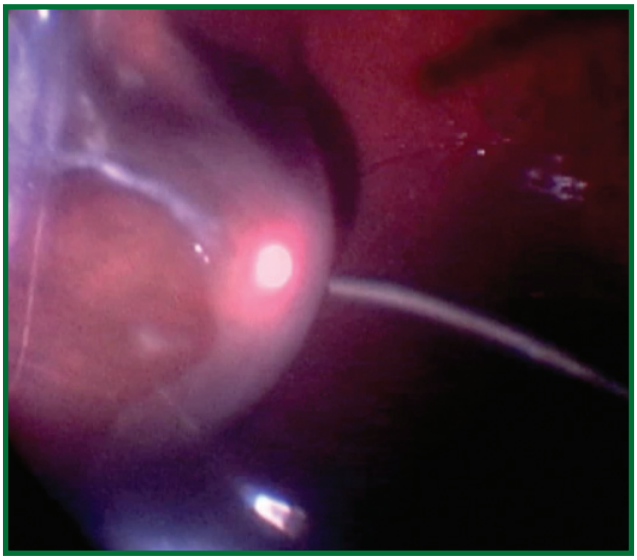

Figure 6. The CONSTELLATION® Vision System has an embedded 532-nm laser with a curved probe. Here the probe is used with chandelier illumination during scleral depression.

> In addition to helping us avoid the main complications associated with vitrectomy in diabetic eyes, the CONSTELLATION® Vision System provides a host of other benefits. It has made setup for procedures quicker than ever ... Everything can be done in a seamless manner.

small probe, with the port closer to the tip than in earlier designs, allows us to get under membranes and work very close to the retinal surface in a safe manner. The efficiency at which the probe cuts, even at 5000 cpm, and the control over duty cycle that the system gives us are also major assets for preventing iatrogenic breaks.

The ability to modify duty cycle to control flow, independent of vacuum and cut rate, allows us to use the vitrectomy probe slowly to shave tissue without it jumping into the probe. Thick blood clots are removed quickly, and membranes can be peeled from blood vessels. The ability to manipulate cuts per minute and duty cycle also expands the utility of the vitrectomy probe. Many tasks that we would have performed with other instruments in the past can be performed with just the probe. We can get under membranes to lift and dissect them. We can use the probe as forceps, scissors or a pick (Figures 2 and 3).

The CONSTELLATION® System also has advanced reflux capabilities, which the surgeon controls with the foot pedal. We can use proportional reflux for membrane dissection and also continuous reflux to "blow" blood and fluid out of the way.

PREVENTING INTRAOPERATIVE BLEEDING

In addition to iatrogenic breaks, intraoperative bleeding is a primary complication in diabetic eyes. One step I often take to reduce the vascularity of the abnormal tissue is to perform an intravitreal injection of bevacizumab within five days prior to vitrectomy (Figure 4).

Also, once inside the eye to treat a diabetic traction detachment, I try to remove all of the vitreous and the blood in the vitreous before addressing the fibrovascular tissue. This improves my view into the eye and allows me to quickly handle any new bleeding that may emerge, before clotting occurs. A strategy I use to prevent bleeding in traction/ rhegmatogenous cases is to visco-dissect the abnormal tissue (Figure 5). This creates a plane between it and the retina so it can be removed more easily with the vitrectomy probe. Again, as I mentioned previously, I am able to work very close to the retina in this scenario, which was unthinkable with earlier technologies.

The multifunctionality of the CONSTELLATION® System vitrectomy probe, as described above, requires fewer instrument exchanges are typically required, which means fewer undesired changes in IOP. When instruments do need to be moved in and out of the eye, however, or when pressure would typically surge after scleral depression, the system's integrated pressurized infusion with IOP control keeps globe pressure steady within +/– 2 mmHg. Flow sensors in the cassette continuously monitor infusion flow and the system directly compensates for that to maintain the desired overall pressure. In contrast to previous strategies for intraoperative IOP control, this occurs quickly and automatically in real time.

A COMPLETE PACKAGE

In addition to helping us address the main complications associated with vitrectomy in diabetic eyes, the CONSTELLATION® Vision System provides a host of other benefits. It has made setup for procedures quicker than ever, and gives the entire case what I call better overall "flowability." Everything can be done in a seamless manner. For example, the embedded 532-nm PUREPOINT® laser comes with a flexible tip laser probe, so we can treat the retina all the way to the ora serrata (Figure 6). This was not possible in phakic eyes with previously available straight probes. The intensity of the laser burns is surgeon-controlled with the foot pedal, and we can transition from liquid to gas to laser and so on, in a seamless manner.

The CONSTELLATION® Vision System has dramatically changed the way we tackle these difficult cases.

Dr. Berrocal is a professor of Ophthalmology at the University of Puerto Rico School of Medicine. She practices in San Juan.

BY CARL D. REGILLO, MD, FACS

Management of Retained Lens Material

Updated surgical techniques and technologies are helping to improve visual outcomes.

Retained lens material (RLM) in the vitreous cavity is a potentially serious complication of modern cataract surgery, estimated to occur in 0.3-1.1% of cases.[1] Several factors have been identified as increasing the risk of RLM, including hypermature, dense brunescent or posterior polar cataracts, zonular compromise, previous vitrectomy and floppy iris syndrome. Any condition predisposing the eye to intraoperative posterior capsular tear, such as diabetes or pseudoexfoliation, also increases the risk of RLM.

Eyes with RLM can develop elevated IOP, corneal edema, vitreous hemorrhage, retinal detachment and persistent intraocular inflammation, including cystoid macular edema (CME), which usually leads to poor visual acuity.

In cases where only a small amount of cortical material is retained, vitreoretinal surgery may not be necessary. Often, these fragments dissolve on their own. In the meantime, the patient should be treated with topical anti-inflammatory drops and watched closely for elevated IOP, CME and retinal detachment. When larger amounts of lens material or nuclear fragments are retained, pars plana vitrectomy (PPV)/lensectomy is required to remove the fragments (Figure 1), with the goals of reducing IOP and inflammation, repairing any retinal breaks or detachments and ultimately restoring visual acuity.

Historically, achieving good visual acuity outcomes after PPV/lensectomy for RLM has been a challenge because complication rates have been high. A look back at all published series since 1980 with 25 or more cases showed that retinal detachments occurred in 8-17% of cases, CME persisted in up to 46% of cases, and visual acuity of 20/40 or better was achieved in only 55% (44-71%) of cases (unpublished data). Based on a retrospective review of all cases of PPV for removal of retained lens fragments performed at Wills Eye Institute from April 1991 through August 1994 (121 eyes),[2] my colleagues and I reported visual acuity of 20/40 or better in 3% of eyes before surgery and 68% of eyes after surgery. Retinal detachments occurred in 19 eyes (16%). Eight were noted at the time of vitrectomy and 11 occurred after vitrectomy. The main causes of poor final visual outcome were retinal detachment and CME. Among patients with a final visual outcome of

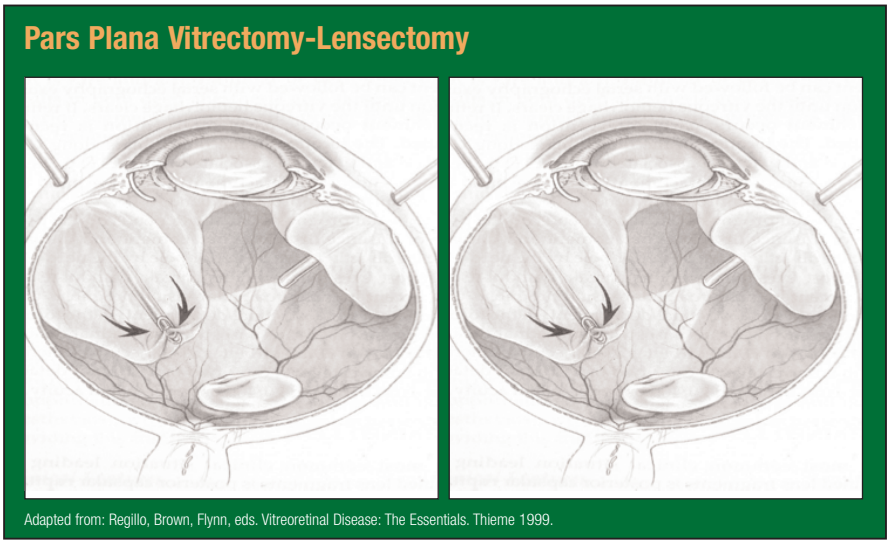

Figure 1. A small amount of cortical material retained in the vitreous cavity following cataract surgery may dissolve on its own. However, when larger lens or nuclear fragments are retained, they should be removed with subsequent pars plana vitrectomy/lensectomy.

20/400 or worse, 33% had a detachment, 22% had CME and 11% had elevated IOP.

Large series published more recently provide additional data. Smiddy and colleagues[3] reported a retinal detachment rate of 8% and final visual acuity of 20/40 or better in 54% of eyes. Scott and colleagues[4] reported a retinal detachment rate of 13% and final visual acuity of 20/40 or better in 56% of eyes, and Merani and colleagues[5] reported a retinal detachment rate of 9% and final visual acuity of 20/40 or better in 71% of eyes.

IMPROVING VISUAL OUTCOMES

Efforts to optimize the final outcomes of PPV/lensectomy for RLM have focused on surgical techniques to minimize complications, in particular, CME, corneal edema and retinal detachment. New technologies, by way of enabling widefield viewing and more controlled, less traumatic surgeries, have been beneficial. Taking advantage of updated surgical techniques and technologies, we have made progress. In updating our previously described Wills Eye series with 115 consecutive cases performed from 2002-2003, my colleagues and I found that, excluding preexisting retinal conditions, 68% of eyes had 20/40 or better visual acuity postoperatively (unpublished data). Eight of the eyes (7%) had retinal detachments, four prior to vitrectomy and four after vitrectomy. Preoperative patient characteristics were similar in both series. Among the 2002-2003 patients, 70% had preoperative visual acuity of less than 20/200.

Reducing complications associated with RLM removal by PPV/lensectomy involves not only the surgery , but management throughout the entire perioperative period, beginning with the cataract surgeon. Here, I describe what are considered best practices for managing RLM based on the literature and collective experience of vitreoretinal surgeons.

Following a capsular rupture, if vitreous has migrated into the anterior chamber, the cataract surgeon should remove it if possible. It is especially important to check for vitreous to the wound, which tends to increase the risk of complications, including endophthalmitis. The cataract surgeon should remove any easily accessible lens material but avoid blind or aggressive maneuvers. Making pars plana incisions to retrieve lens material is not recommended. The cataract surgeon should proceed with IOL implantation if it can be done safely with the IOL securely in place. Wounds should be sutured so they remain sealed during any subsequent surgery.

Immediately following the cataract surgery procedure, the cataract surgeon should initiate aggressive treatment for inflammation with steroid drops every 2 hours while the patient is awake as well as nonsteroidal anti-inflammatory drops. Drops to control IOP should also be prescribed. Within 1 week of cataract surgery, the patient should see a vitreoretinal specialist for a consultation.

It is not completely clear how the duration of time before PPV/lensectomy affects outcomes in RLM cases, but the general consensus is it should be performed within 3 weeks of the cataract procedure. In many cases, waiting a week or two is beneficial because it allows for some resolution of corneal edema and the acute inflammation associated with the cataract surgery. However, PPV/lensectomy should be performed sooner in some situations. If IOP remains significantly elevated despite treatment, I schedule surgery to take place within 48 hours or so after my consultation. Also, because corneal edema usually limits my view into the eye when I first see these patients, I perform a B-scan to make sure the retina is not detached. If it is, I proceed to the OR immediately.

Reducing complications associated with RLM removal by PPV/lensectomy involves not only the surgery , but management throughout the entire perioperative period, beginning with the cataract surgeon.

In all RLM cases, prior to vitrectomy, even if an IOL was implanted at the time of cataract surgery, I obtain all of the measurements and perform the IOL calculations necessary for IOL placement. This allows me, at the end of my procedure, to place the IOL if it is not already there, or to replace it if it is not secure.

INTRAOPERATIVE TECHNIQUES AND TIPS

Visualization is often a challenge during PPV/lensectomy for RLM. The cornea may not be clear due to edema, and the pupil may be small because of inflammation. The wide-field viewing systems and wide-angle illumination probes available for today's surgical platforms are an asset in situations like this, and I do not hesitate to manually stretch the pupil.

My preferred surgical approach is a three-port, 23-gauge vitrectomy. If the RLM to be addressed consists of small fragments and does not include much nuclear material, it is often possible to remove it using only the vitrectomy cutting probe. It can be helpful to utilize the light pipe to guide the fragments into the cutter.

For moderate sized or more dense material, emulsification with a phacofragmatome, i.e., pars plana lensectomy, is neces-

sary. At this point, the case becomes much more challenging because phaco in the posterior segment increases the risk for retinal tears and detachments. Avoiding the creation of retinal breaks with the phaco tip and ensuring all RLM is removed from the anterior chamber and posterior segment all the way to the periphery are primary safety and efficacy concerns. Frequently, rather than floating freely, fragments are embedded deep into the vitreous or far anteriorly over the pars plana area. Therefore, ensuring the vitrectomy is complete and the hyaloid is lifted from the retinal surface and carefully inspecting the retinal periphery and vitreous base with scleral depression are key factors for success. Triamcinolone is a useful adjunct for improving visualization of vitreous gel and confirming complete vitrectomy has been achieved.

Regardless of the surgical platform and phacofragmentation technology being employed, having a good hold of the lens material at the tip is crucial. When the fragments are not too dense, standard phaco settings do the job adequately. However, if emulsification is not progressing in a timely manner and the lens fragments are not holding well to the tip, I do not hesitate to gradually increase vacuum and phaco power. Under suction, I engage the fragments and bring them to the mid-vitreous, away from ocular structures, to emulsify them. I usually hold the light pipe behind the fragments for extra support.

After it appears that all RLM is removed, the anterior chamber should be irrigated to remove any fragments that may be trapped in the angle. At the end of the case, the periphery should be meticulously inspected for breaks. If any are present, they should be treated on the spot with laser. Finally, a commonly used strategy to help control postoperative inflammation is to leave a small amount of triamcinolone (2 mg/0.05 ml) in the eye.

Depending on where I am performing a particular case, I use either the ACCURUS® Surgical System (Alcon) or the CONSTELLATION® Vision System (Alcon). The ACCURUS® System has worked well for me in these cases, but I have found the CONSTELLATION® System to be somewhat more efficient when I am using only the vitrectomy probe to remove small lens fragments because of its higher aspiration in conjunction with improved IOP control.

I have also found that when I need to use the fragmatome, the CONSTELLATION® System emulsifies the largest and densest fragments more efficiently. It includes integrated pressurized infusion with IOP control, which not only keeps the globe from collapsing from high suction forces, but also automatically maintains IOP in the surgeon's desired range throughout the entire procedure. Less IOP fluctuation means a more stable and controlled, gentler procedure. Currently, the fragmatome for the CONSTELLATION® Vision System is 20 gauge, so when I need it, I enlarge one of my 23-gauge sclerotomies to introduce it into the eye.

Another option for lensectomy in RLM cases is to use the INFINITI® Vision System (Alcon) with the OZil® torsional phaco handpiece. I use this approach when I am dealing with dense and hard RLM and do not have access to the CONSTELLATION® System for a particular case. Surgeons Sunir Garg, MD, and R. Gary Lane, MD, recently published a paper on this.[6] Torsional phaco tends to be more efficient than traditional phaco. It creates less turbulence in the eye and draws lens fragments to the phaco tip, rather than repulsing them, which helps to protect the retina and decrease the risk of breaks. The OZil® torsional handpiece recently became available with the CONSTELLATION® System as well.

CLOSE POST-OP MONITORING

Following PPV/lensectomy for RLM, it is important to closely monitor patients for inflammation, elevated IOP and signs of peripheral retinal tears or detachments. I see these patients one day, 1 week, 4 weeks and 8 weeks after surgery. I follow them for no less than 3 months. I prescribe topical steroids and topical nonsteroidal anti-inflammatory drops, which are tapered slowly over 6 to 8 weeks, or longer if necessary. If visual acuity is not improving as expected by the four-week visit, I obtain OCT scans to check for CME. If CME is detected, I treat it aggressively with a sub-Tenon's or intravitreal injection of triamcinolone.

Once the course of topical anti-inflammatory treatment is complete, if no CME is present and visual acuity has reached or is close to its potential, the patient returns to the cataract surgeon for a refraction. I usually see the patient once more at six months after PPV/lensectomy. If no problems have arisen by that time, I can be confident that the best possible outcome has been achieved.

Dr. Regillo is the director of the Wills Clinical Retina Research Unit and professor of Ophthalmology at Thomas Jefferson University School of Medicine in Philadelphia.

REFERENCES

1. Scott IU, Flynn HW. Retained lens fragments after cataract surgery. *Ophthalmol Clin N Am* 2001;14:675-679.
2. Borne MJ, Tasman W, Regillo C, Malecha M. Outcomes of vitrectomy for retained lens fragments. *Ophthalmology* 1996;103(6):971-976.
3. Smiddy WE, Guererro JL, Pinto R, Feuer W. Retinal detachment rate after vitrectomy for retained lens material after phacoemulsification. *Am J Ophthalmol* 2003;135(2): 183-187.
4. Scott IU, Flynn HW, Smiddy WE, et al. Clinical features and outcomes of pars plana vitrectomy in patients with retained lens fragments. *Ophthalmology* 2003;110(8):1567-1572.
5. Merani R, Hunyor AP, Playfair TJ, et al. Pars plana vitrectomy for the management of retained lens material after cataract surgery. *Am J Ophthalmol* 2007;144(3):364-370.
6. Garg SJ, Lane RG. Pars plana torsional phacoemulsification for removal of retained lens material during pars plana vitrectomy. *Retina* 2011;31(4):804-805.

BY WAYNE A. SOLLEY, MD

Removing an IOL from the Vitreous Cavity

A new approach eliminates the need for a limbal incision and proves to be more efficient.

Even though modern cataract surgery techniques and new IOL designs have significantly reduced all types of associated complications, the potential for IOL dislocation still exists. It has been estimated to occur in 0.2% to 3% of cases.[1,2] The extent of dislocation can range from slight decentration to partially out of the capsular bag to complete luxation into the posterior segment. Pseudoexfoliation is a common cause of both in-the-bag and out-of-the-bag dislocations, and out-of-the-bag scenarios are often due to some sort of capsular compromise, such as a rupture or tear, at the time of surgery.[3,4] Dislocations can occur during cataract surgery or even months or years afterward.[4-7]

As long as a patient's overall health and ocular health permit it, surgery to remove, exchange or reposition the IOL is typically recommended in order to alleviate potentially annoying symptoms and restore optimal vision. In some cases, an anterior-segment (limbal) surgical approach can be used. However, when the IOL has dislodged fully into the vitreous cavity, pars plana vitrectomy (PPV), which is considered to be safe and effective for this purpose, is a much safer approach.[8]

While vitreoretinal surgeons don't see as many cases of dislocated IOLs as other posterior segment conditions and pathology, dislocated IOLs are not rare in our operating rooms. Given the increasing number of patients who undergo cataract surgery each year — as well as the aging of the overall population — we can reasonably expect to be called on to manage these cases more frequently in the future.

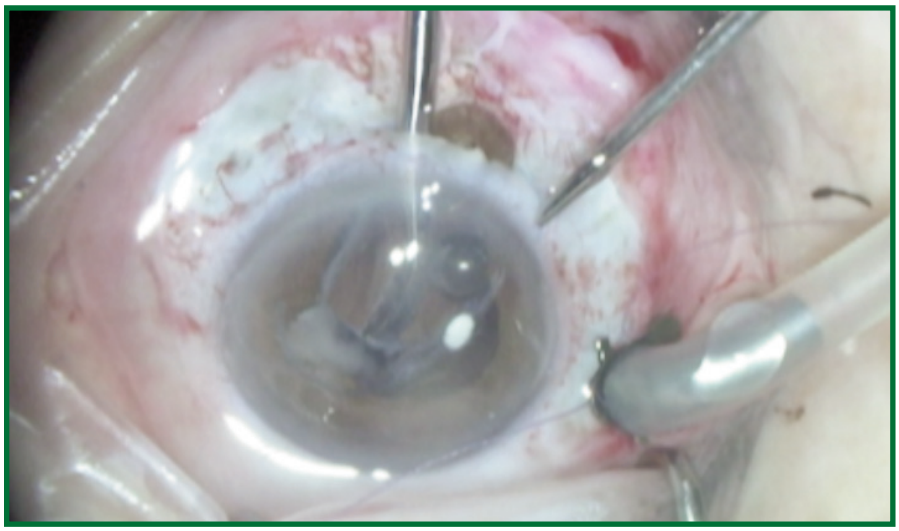

Figure 1. Removal of a dislocated IOL by raising it into the anterior chamber requires a large corneal limbal incision, which can be less than ideal for several reasons, including the risk of hypotony and longer healing time for the patient.

I have recently begun using a new technique to remove IOLs that have dislodged and fallen into the vitreous cavity. I use the CONSTELLATION® Vision System for PPV, then cut the IOL into several strips and remove each one through the pars plana. With this method, there is no need to make a corneal limbal incision or raise the IOL into the front of the eye. I find this strategy to be more efficient for me and less invasive for my patients. Here, I explain the technique and why the CONSTELLATION® System is a good platform from which to perform it.

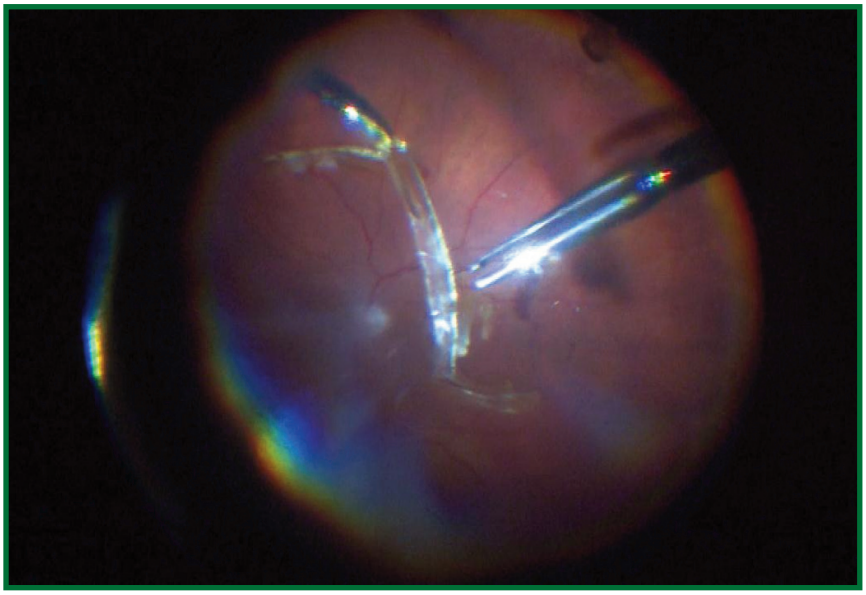

Figure 2. A thin strip of dislocated IOL, which had been segmented using Packer/Chang IOL Cutters, just prior to removal through the pars plana.

OLD VS. NEW TECHNIQUE

For patients, the dislocation of an IOL into the vitreous can be an unsettling turn of events. Vision disruption is often sudden and profound. Once the cataract surgeon refers a patient to me, if it has not already been done, I reassure him that his vision will be fine by having him look through a +10 lens. In general, unless a dislocated IOL has caused a retinal detachment,[9] an IOL in the vitreous is not an emergency situation. Nevertheless, in the vast majority of cases, I schedule the procedure for my next surgical day.

Some vitreoretinal surgeons choose to implant a completely new IOL, reposition the dislocated IOL in the sulcus or use various suturing techniques to keep it in place. I prefer to simply remove the dislocated IOL and allow the cataract surgeon to choose the next step for each patient. In some cases, an IOL may not be stable in the sulcus, and if a lens was originally implanted in the capsular bag, sewing it in may not be the best solution either. One could make an argument that rather than simply removing a dislocated IOL, the vitreoretinal specialist should exchange or reposition the IOL to spare the patient an additional surgery at a later date. However, I've never had a patient upset with my approach and the cataract surgeons I work with like it as well.

In the past, I removed IOLs from the vitreous, using the technique that I, and most vitreoretinal surgeons, learned in training. I would perform a three-port vitrectomy, freeing the IOL from all of the vitreous gel enveloping it, raising the IOL into the anterior chamber, and making a beveled corneal limbal incision through which I would remove the IOL. One of the drawbacks to this technique was the need to use a corneal incision in addition to the three PPV sclerotomies. Often, it wasn't easy to create an ideal beveled wound because the cataract surgeon had already operated through that area, and with time, thinning and scarring of the limbus ensued. In addition, the corneal wound had to be relatively large and would have to be gaped to pull the IOL through, so hypotony was a frequent concern. It was a challenge, too, to get the IOL into the anterior segment and keep it there for the necessary maneuvers. Another drawback was dragging the IOL out of an anterior segment wound, which sometimes lead to iris prolapse, especially with light irides, or damage the corneal endothelium or Descemet's. Furthermore, it was often difficult to tightly close the corneal wound without several sutures and the resulting threat of a large amount of induced corneal astigmatism. While this method was effective and not usually technically difficult, I found it to be tedious and time-consuming because it required numerous incisions, sutures and intraocular maneuvers that were not part of my normal routine.

STEPS IN IOL REMOVAL

With my new method for removing posteriorly dislocated IOLs, I set up for a standard three-port 20-gauge vitrectomy with a chandelier light. As with the old method, it is important to accomplish a complete vitrectomy so the IOL is free of vitreous, especially near the sclerotomies. With the IOL free from vitreous and (usually) lying on the posterior pole, I enlarge the 10 o'clock sclerotomy (my right-hand side) to accommodate a pair of Packer/Chang IOL Cutters (MST, Redmond, Wash.). These microscissors are designed for cataract surgeons to use through the paracentesis and they have exceptional cutting ability. I use a handheld or fundus contact lens to help me see, so I can safely grasp the IOL with forceps,

> Managing a posteriorly dislocated IOL completely in the posterior segment allows me to reduce the risk of several intraoperative complications, work more efficiently ... and offer patients a more comfortable recovery period.

then I elevate the IOL into the mid-vitreous cavity. Next, using chandelier illumination and the BIOM® wide-angle viewing system (Insight Instruments), forceps in my left hand and the scissors in my right hand, I cut the IOL into several thin strips. When it is in sections, I use the same enlarged sclerotomy I used for the scissors to remove the pieces one at a time with forceps.

Initially, I was concerned that cutting the IOL in this manner would create jagged edges or cause the pieces to swirl around in the infusion currents, but they just fall gently back onto the posterior segment when cut. I am very happy with how the technique has worked in the cases I've done so far. One caveat worth mentioning: this procedure will not work with a polymethylmethacrylate (PMMA) lens — only silicone and acrylic lenses are flexible enough to be cut with scissors. Rigid PMMA lenses must be removed as a single unit, and this is most easily done through a limbal incision.

I follow the patients for approximately a month after the procedure, seeing them at 1 day, 1 week and 1 month after surgery to check for elevated IOP and other potential postoperative complications, such as cystoid macular edema and retinal detachment.[6, 10-11] I have experienced no complications to date, and, because the anterior segment has been manipulated much less and suturing is not as pronounced, patients have been more comfortable after surgery with this new method. All patients have been ready to return to the cataract surgeon following their 1-month visit with me.

TRUST IN YOUR TECHNOLOGY IS KEY

I like using the CONSTELLATION® Vision System for this new technique for several reasons. First, during manipulation of the IOL, it is important that pieces not "catch" onto any vitreous. With the ULTRAVIT® vitrectomy probe for the CONSTELLATION® System, I can cut at up to 5,000 cpm and also control the duty cycle for an efficient core vitrectomy, as well as minimize vitreoretinal traction in the periphery. These features enable an efficient vitrectomy, in some cases 4 to 5 minutes, which means I can seamlessly insert a dislocated IOL case into any part of any surgical day. While the new technique could also be performed with the ACCURUS® Surgical System or other state-of-the-art vitrectomy systems with chandelier lighting (to free up both hands for grasping and cutting), the Chandelier Lighting System available for the CONSTELLATION® System is brighter and has a broad illumination angle of 106º, providing excellent visualization for the necessary IOL manipulations described.

Managing a posteriorly dislocated IOL completely in the posterior segment allows me to reduce the risk of several intraoperative complications, work more efficiently in the area of the eye where I am most comfortable, and offer patients a more comfortable recovery period. This type of case also illustrates how today's vitreoretinal surgical technologies open the door for managing more types of cases with smaller-gauge instruments. I plan to remove my next dislocated IOL with the CONSTELLATION® System using a 23-gauge approach (provided that a 23-gauge forceps will hold the IOL steady enough for cutting). This will take the new technique another step forward, incorporating all of the benefits of microsurgery.

Dr. Solley specializes in the diagnosis and treatment of diseases of the retina and vitreous. He practices with Texas Retina Associates, which has 13 offices throughout the state.

REFERENCES

1. Gimbel HV, Condon GP, Kohnen T, Olson RJ, Halkiadakis I. Late in-the-bag intraocular lens dislocation: incidence, prevention, and management. *J Cataract Refract Surg* 2005;31(11):2193-2204.
2. Mönestam EI. Incidence of dislocation of intraocular lenses and pseudophakodonesis 10 years after cataract surgery. *Ophthalmology* 2009;116(12):2315-2320.
3. Hayashi K, Hirata A, Hayashi H. Possible predisposing factors for in-the-bag and out-of-the-bag intraocular lens dislocation and outcomes of intraocular lens exchange surgery. *Ophthalmology* 2007;114(5):969-975.
4. Davis D, Brubaker J, Espandar L, et al. Late in-the-bag spontaneous intraocular lens dislocation: evaluation of 86 consecutive cases. *Ophthalmology* 2009;116(4):664-670.
5. Jakobsson G, Zetterberg M, Lundstro M, Stenevi U, Grenmark R, Sundelin K. Late dislocation of in-the-bag and out-of-the bag intraocular lenses: ocular and surgical characteristics and time to lens repositioning. *J Cataract Refract Surg* 2010;36(10):1637-1644.
6. Kim SS, Smiddy WE, Feuer W, Shi W. Management of dislocated intraocular lenses. *Ophthalmology* 2008;115(10):1699-1704.
7. Gross JG, Kokame GT, Weinberg DV. In-the-bag intraocular lens dislocation. *Am J Ophthalmol* 2004;137(4):630-635.
8. Seo MS, Kim CR, Nah HJ, et al. Management of posteriorly dislocated intraocular lens using pars plana vitrectomy. *Korean J Ophthalmol* 2000;14(2):80-84.
9. Campo RV, Chung KD, Oyakawa RT. Pars plana vitrectomy in the management of dislocated posterior chamber lenses. *Am J Ophthalmol* 1989;108(5):529-534.
10. Mello MO Jr, Scott IU, Smiddy WE, Flynn HW, Feuer W. Surgical management and outcomes of dislocated intraocular lenses. *Ophthalmology* 2000;107(1):62-67.
11. Sarrafizadeh R, Ruby AJ, Hassan TS, et al. A comparison of visual results and complications in eyes with posterior chamber intraocular lens dislocation treated with pars plana vitrectomy and lens repositioning or lens exchange. *Ophthalmology* 2001;108(1):82-89.

BY TIMOTHY G. MURRAY, MD, MBA, FACS

Combined Surgery for Retinal Pathology and Cataract

A single procedure is less burdensome for patients and facilitates faster visual recovery.

With the aging of the population in the United States, vitreoretinal surgeons are increasingly faced with the challenge of managing posterior segment pathology in patients who have coexisting cataract. On one hand, we know that cataract must be addressed in order for patients to reach their visual potential following retinal surgery. On the other hand, we know cataract surgery following retinal surgery can lead to a reintroduction of retinal problems. This scenario is further complicated in my practice because its primary focus is ocular oncology. I cannot proceed with treatment of cataract or posterior segment pathology until a patient's intraocular malignancy has been stabilized.

The approach to management of retinal pathology and co-existing cataract has begun to evolve. Rather than addressing the cataract first and performing pars plana vitrectomy (PPV) at a later time, or vice versa, surgeons are choosing more often to treat both in a single combined procedure. Combined procedures are an opportunity for patients to undergo one surgery instead of two with accelerated normalization of the ocular anatomy and rehabilitation of visual function. Advances in technology, particularly in combination anterior segment/posterior segment surgical platforms, have enabled us to achieve favorable results in this manner. I recently conducted a study to evaluate the merits of the combined approach (See "Retrospective Review of Combined Surgery Series") and here I describe a case that illustrates how it is successfully used in my practice.

SINGLE SURGERY FOR COMPLEX RETINAL DETACHMENT AND CATARACT

The patient is a 75-year-old Hispanic female with malignant posterior uveal melanoma of the left eye. In May 2006, with visual acuity of 5/200, she was treated with iodine-125 plaque brachytherapy. Over the next 12 months, the tumor regressed and vision improved to 20/40. Eighteen months after brachytherapy, the eye developed radiation retinopathy, which was treated over the course of 24 months with intravitreal bevacizumab. Vision stabilized at 20/50; however, likely due to the retinopathy, a complex hemorrhagic retinal detachment as well as a visually significant cataract emerged. The retinal detachment was progressive, and the patient experienced a significant decline in visual acuity.

Since the patient's melanoma had an excellent response to brachytherapy that was documented over a 4-year period, we were able to consider surgical repair of the complex retinal detachment to restore the ocular anatomy and vision. Because the cataract was contributing to visual acuity loss and would confound the posterior segment repair, we elected to perform a single combined procedure. After we confirmed the tumor was involuted and saw no evidence of active melanoma on exam, imaging or ultrasound, we scheduled surgery.

Currently, I perform all of my combined procedures with the CONSTELLATION® Vision System (Alcon) and 23-gauge instrumentation, including the EdgePlus® valved entry system. The valved cannulas may improve posterior segment fluidics during vitrectomy, which is a key benefit in combined surgeries. The valved cannulas may improve posterior segment fluidics during vitrectomy. They do not attract tissue to the sclerotomy sites, and they make sclerotomy plugs unnecessary.

I begin each combined procedure by displacing the conjunctiva and placing the first 23-gauge trocar in the inferotemporal quadrant. I introduce it obliquely, at a 30º insertion angle, followed by a 90º rotation to clear the

Retrospective Review of Combined Surgery Series

Recent technological advances designed to enhance surgical safety and efficiency are making single combined procedures for concomitant vitreoretinal disease and cataract a more attractive option for both patients and surgeons. To more closely evaluate how combined procedures performed with the newest surgical platforms impact visual acuity outcomes and perioperative complications, we recently carried out a retrospective review of cases managed from January 2006 to March 2009 at the Bascom Palmer Eye Institute in Miami.[1]

The review included 114 eyes of 111 patients who had complex vitreoretinal pathology as well as anterior segment lenticular changes. All patients underwent sutureless 23-gauge vitrectomy and phacoemulsification. Posterior chamber IOLs were successfully placed in all of the eyes.

Early in the series, surgeons utilized the ACCURUS® Surgical System (Alcon), but later transitioned to the CONSTELLATION® Vision System (Alcon). The CONSTELLATION® System integrates a 5000 cpm vitrectomy probe with duty cycle control, real-time monitoring and adjustment of IOP, high-brightness xenon illumination, a 532-nm laser and torsional phacoemulsification.

The mean age of the patients in the series was 76 years, and the most common indications for surgery were intractable cystoid macular edema, epiretinal membrane and retinal detachment. Approximately 42% of the patients had an intraocular malignancy, 26% had epiretinal membrane and vitreomacular traction alterations, and approximately 23% had diabetic tractional complications at the time of surgery. Average follow-up time was 8 months (range, 3 months to 2 years).

No intraoperative complications occurred, and no cases of endophthalmitis developed. Capsular tears occurred in approximately 13% of cases, and four eyes developed hypotony. Mean logMAR visual acuity was 20/192 at baseline and it improved to 20/129 3 months after the procedure (p=0.005). A two-line or greater improvement in visual acuity was seen in 76% of patients.

Our results indicate that treating co-existing cataract and retinal disease in a single surgery is a safe and effective option in the eyes studied, which are among those at the highest risk for complications.

— Timothy G. Murray, MD, MBA, FACS

REFERENCE

1. Sisk RA, Murray TG. Combined phacoemulsification and sutureless 23-gauge pars plana vitrectomy for complex vitreoretinal diseases. *Br J Ophthalmol* 2010;94(8):1028-1032.

suprachoroidal space and create a beveled incision. A second instrument is not needed to separate the trocar from the cannula. After visually confirming the trocar is in the intravitreal space, I turn on the infusion line and attach it to the trocar. When IOP stabilizes, I insert the superotemporal and superonasal trocars using the same angled approach.

With the trocars in place, I begin the cataract removal procedure with a clear corneal incision. For phacoemulsification, I use the OZil® torsional handpiece technology (Alcon) that is available with the CONSTELLATION® System. I find that torsional phaco enhances my ability to safely and effectively manage cases such as this complex retinal detachment and cataract. Torsional energy provides efficient dissolution of hard nuclei and minimizes energy transfer to adjacent tissues. Working in conjunction, OZil® torsional handpiece and the CONSTELLATION® System's advanced fluidics maintain the anterior chamber through the duration of the procedure. Once the cataractous crystalline lens is removed, I insert the IOL, typically a foldable three-piece acrylic model. Because the eye must still undergo the posterior segment procedure, I inject visco-elastic into the anterior chamber to help keep it stable. To further ensure anterior chamber stability, I suture the cataract wound with 10-0 nylon.

At this point, I turn my attention to the posterior segment. The 23-gauge cutter and endoilluminator are placed into the eye. Under contact 130º widefield viewing, I perform an aggressive PPV, paying specific attention to removal of the posterior hyaloid and dissection of any preretinal membranes. I identify any preexisting retinal breaks and perform an air-fluid exchange. Next, I introduce the 23-gauge Alcon Illuminated Flex Curved Laser Probe into the eye and close all of the retinal breaks. In this particular case, I covered the tumor with confluent laser. With a soft-tip 23-gauge cannula, I remove the remaining subretinal and pre-retinal fluid. Sometimes, soft-tip instruments may not pass through the valved cannula easily. To facilitate this, I displace one of the leaflets of the valved cannula with a 30-gauge needle and slide the instrument along the shaft of the needle into the cannula.

Intraocular tamponade, typically C3F8 gas (16-18%) or silicone oil (1000-5000 centistoke), is the next step. To avoid an IOP spike and ensure an excellent fill, I make use of the vent that is provided with each set of trocars. I can then remove the trocars from the eye, which I do obliquely as I did at insertion. If I have any concern about wound sealability, I do not hesitate to suture. After confirming that IOP is 10-15 mmHg, I administer subconjunctival injections of

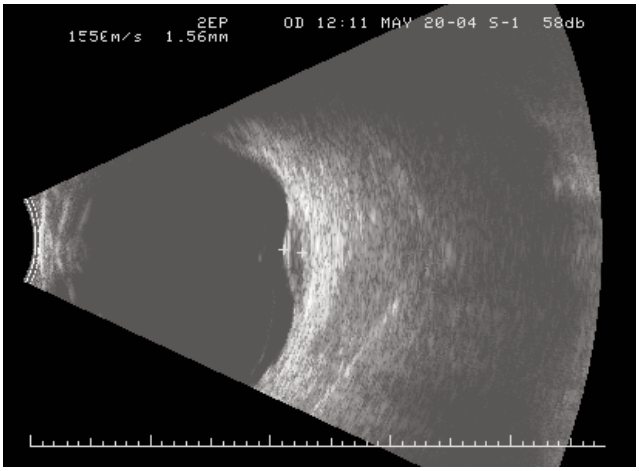

Figures 1 and 1a. Malignant posterior uveal melanoma of the left eye in a 75-year-old Hispanic female.

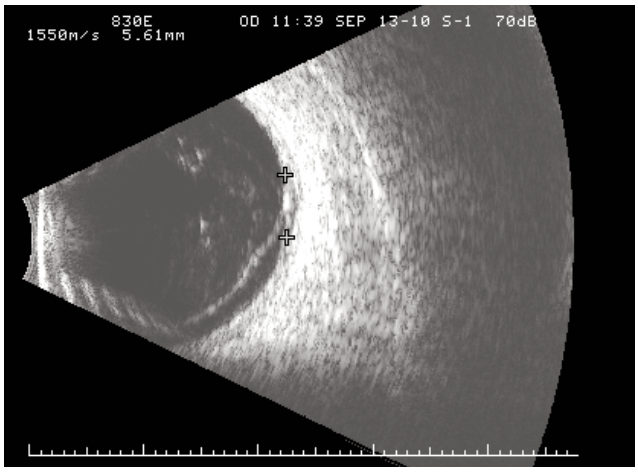

Figure 2. Eighteen months after successful brachytherapy, the patient's left eye developed radiation retinopathy, which was treated over the course of 24 months with intravitreal bevacizumab. Vision stabilized at 20/50; however, a complex and progressive hemorrhagic retinal detachment developed.

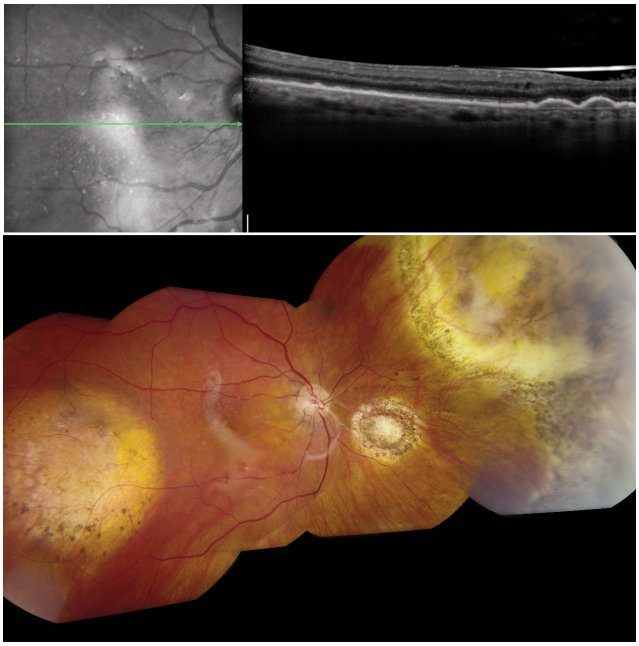

Figures 3 and 3a. The patient's left eye following a single combined 23-gauge procedure for cataract and repair of a complex retinal detachment. Prior to surgery a favorable response to brachytherapy for malignant uveal melanoma had been documented over a 4-year period.

dexamethasone and gentamicin. I place the injections 180º away from the sclerotomy sites to prevent the medication from migrating out of the wounds. Finally, I apply topical antibiotics and steroids.

After surgery, I have patients use topical antibiotics twice a day for 1 week and a topical steroid twice a day for 2 weeks and once a day for a final week. Strict face-down positioning is crucial to ensure a favorable outcome. I see the patients 1 day, 1 week, 1 month and 3 months after surgery. For this particular patient, postoperative visual acuity improved to 20/100 from 1/200 pre-operatively. Ongoing follow-up to monitor the malignant melanoma continues.

A SIGNIFICANT ADVANCE

The CONSTELLATION® Vision System has greatly reduced the number of complications I see, both intra-operatively and postoperatively, in my small-gauge combined anterior/posterior segment procedures. I consider the ability to achieve such favorable outcomes in cases of complex retinal disease and co-existing cataract a significant advance in vitreoretinal surgery and expect most surgeons to continue to integrate this approach into their practices.

Dr. Murray is a professor of Ophthalmology and director of the Ocular Oncology Service at Bascom Palmer Eye Institute, University of Miami Miller School of Medicine.

CONSTELLATION® Vision System Indications for Use With Laser

Indications for Use: The CONSTELLATION® Vision System is an ophthalmic microsurgical system that is indicated for both anterior segment (i.e., phacoemulsification and removal of cataracts) and posterior segment (i.e., vitreoretinal) ophthalmic surgery.

The PUREPOINT® Laser is indicated for use in photocoagulation of both anterior and posterior segments of the eye including:

- Retinal photocoagulation, panretinal photocoagulation and intravitreal endophotocoagulation of vascular and structural abnormalities of the retina and choroid including: Proliferative and nonproliferative retinopathy (including diabetic); choroidal neovascularization secondary to age-related macular degeneration; retinal tears and detachments; macular edema, retinopathy of prematurity; choroidal neovascularization; leaking microaneurysms.
- Iridotomy/Iridectomy for treatment of chronic/primary open angle glaucoma, acute angle closure glaucoma and refractory glaucoma.
- Trabeculoplasty for treatment of chronic/primary open angle glaucoma and refractory glaucoma.
- And other laser treatments including: internal sclerostomy; lattice degeneration; central and branch retinal vein occlusion; suturelysis; vascular and pigment skin lesions.

Caution: Federal (USA) law restricts this device to sale by, or on the order of, a physician.

Contraindications: Patients with a condition that prevents visualization of target tissue (cloudy cornea, or extreme haze of the aqueous humor of the anterior chamber of vitreous humor) are poor candidates for LIO delivered laser treatments.

Complications: Corneal burns, inflammation, loss of best-corrected visual acuity, loss of visual field and transient elevations in intraocular pressure can occur as a result of ophthalmic laser treatment. Unintentional retinal burns can occur if excessive treatment beam power or duration is used.

Warnings and Precautions:

- The disposables used in conjunction with Alcon instrument products constitute a complete surgical system. Use of disposables and handpieces other than those manufactured by Alcon may affect system performance and create potential hazards.
- Attach only Alcon supplied consumables to console and cassette luer fittings. Do not connect consumables to the patient's intravenous connections.
- Mismatch of consumable components and use of settings not specifically adjusted for a particular combination of consumable components may create a patient hazard.
- Vitreous traction has been known to create retinal tears and retinal detachments.
- The closed loop system of the CONSTELLATION® Vision System that adjusts IOP cannot replace the standard of care in judging IOP intraoperatively. If the surgeon believes that the IOP is not responding to the system settings and is dangerously high, this may represent a system failure. Note: To ensure proper IOP Compensation calibration, place infusion tubing and infusion cannula on a sterile draped tray at mid-cassette level during the priming cycle.
- Leaking sclerotomy may lead to post operative hypotony.
- Back scattered radiation is of low intensity and is not harmful when viewed through a protective filter. All personnel in the treatment room must wear protective eyewear, OD4 or above at 532nm, when the system is in Standby/Ready mode as well as during treatment. The doctor protection filter is an OD greater than 4 at 532nm.
- Important Safety Information: Warnings and Cautions: A complete listing is available in the CONSTELLATION® Vision System Operators Manual. To obtain a copy, please contact Alcon Customer Service.

INFINITI® System Indications for Use

Indication: The INFINITI® Vision System with OZil® IP is indicated for emulsification and removal of cataracts, vitreous aspiration and cutting associated with anterior vitrectomy, and bipolar coagulation.

Caution: Federal (USA) law restricts this device to sale by, or on the order of, a physician.

Warnings: Appropriate use of INFINITI® Vision System parameters and accessories is important for successful procedures. Use of low vacuum limits, low flow rates, low bottle heights, high power settings, extended power usage, power usage during occlusion conditions (beeping tones), failure to sufficiently aspirate viscoelastic prior to using power, excessively tight incisions, and combinations of the above actions may result in significant temperature increases at incision site and inside the eye, and lead to severe thermal eye tissue damage.

Adjusting aspiration rates or vacuum limits above the preset values, or lowering the IV pole below the preset values, may cause chamber shallowing or collapse which may result in patient injury.

When filling handpiece test chamber, if stream of fluid is weak or absent, good fluidics response will be jeopardized. Good clinical practice dictates the testing for adequate irrigation and aspiration flow prior to entering the eye.

Ensure that tubings are not occluded or pinched during any phase of operation.

The consumables used in conjunction with Alcon instrument products constitute a complete surgical system. Use of consumables and handpieces other than those manufactured by Alcon may affect system performance and create potential hazards.

AEs/Complications: Use of the NeoSoniX®, OZil® torsional, U/S, or AquaLase® handpieces in the absence of irrigation flow and/or in the presence of reduced or lost aspiration flow can cause excessive heating and potential thermal injury to adjacent eye tissues.

ATTENTION: Reference the Directions for Use labeling for a complete listing of indications, warnings and precautions.

Disclosures

Maria H. Berrocal, MD, has consulted for Alcon and Alimera.

Timothy G. Murray, MD, is a consultant for Alcon and ThromboGenics, Inc.

Carl D. Regillo, MD, has received research support from, and provided consulting for, Alcon and Bausch + Lomb. He has consulted for Abbott Medical Optics (AMO).

Wayne A. Solley, MD, has received honoraria and educational grants from Alcon.

To watch videos of the procedures discussed in these articles, visit the *Retinal Physician* home page (www.retinalphysician.com) and click on the DIGITAL SUPPLEMENTS tab.

VIT11915JS

Editorial Staff
EDITOR-IN-CHIEF, *Retinal Physician*: Jason S. Slakter, MD
EDITORIAL MANAGER, SPECIAL PROJECTS: Angela Jackson
EDITOR, SPECIAL PROJECTS: Leslie Goldberg
CONTRIBUTING EDITOR: Desiree Ifft

Design and Production
PRODUCTION DIRECTOR: Leslie Caruso
PRODUCTION MANAGER: Stacy Drossner
ART DIRECTOR: Michael F. Higgins

Editorial and Production Offices
323 Norristown Road, Suite 200, Ambler, PA 19002
Phone: (215) 646-8700

Business Staff
GROUP PUBLISHER: Douglas A. Parry
ASSOCIATE PUBLISHER: Dan Marsh
MARKETING MANAGER: Amy Wauhop
PROMOTIONAL EVENTS MANAGER: Michelle Kieffer
CIRCULATION DIRECTOR: Deb Benward